



WHY DO ZACKIE ACHMAT, NATHAN GEFFEN AND MARK HEYWOOD WANT PREGNANT AFRICAN WOMEN AND THEIR BABIES TO BE GIVEN AZT?*

WHAT AZT DOES TO UNBORN AND NEWLY BORN CHILDREN

100 mg	A-2169	Lot 921178011
SIGMA[®]		
3'-AZIDO-3'-DEOXYTHYMIDINE		
(AZT; Azidothymidine) (30516-87-1)		
TOXIC Toxic by inhalation, in contact with skin and if swallowed. Toxic organically bound metals may move if you feel unwell. Get medical advice (phone 0800 134567) where possible). Wear protective clothing.		Decompose
		Store at less than 0°C
		C₁₀H₁₂N₂O₂ FW 267.2 Purity > 99% (HPLC) <small>For laboratory use only. Not for clinical, household or other uses.</small>
 SIGMA CHEMICAL CO. INC. 1000 BROADWAY, NEW BRUNSWICK, NJ 07102		

Reports from the medical literature compiled by Adv Anthony Brink, chairman of the **Treatment Information Group**

'AZT FOR PREGNANT WOMEN'

Treatment Action Campaign street demonstration placard

'By increasing the availability of drugs, particularly for preventing mother to child transmission, the government is going to save lives.'

Zackie Achmat, TAC leader, *Mail&Guardian*, 28 October 2006

'Toxic Giftig Toxique Toxico Tossico Vergiftig ... TOXIC Toxic to inhalation, in contact with skin and if swallowed. Target organ(s): Blood Bone marrow. In case of accident or if you feel unwell, seek medical advice immediately (show the label where possible). Wear suitable protective clothing.'

Label on 25 mg bottles of AZT supplied by Sigma-Aldrich Chemie GmbH for research use, bearing an orange stripe imprinted with a skull and crossbones icon to signify potentially fatal toxic chemical hazard – the latest version of which also carries a cancer warning

'Our findings support the hypothesis of a link between mitochondrial dysfunction [*in babies and infants*] and the perinatal administration of prophylactic nucleoside analogues.' (Eight children were born with severely impaired energy metabolism and corresponding muscle and other cell damage, manifesting in heart muscle injury and muscle weakness generally. Five children, of whom two died, presented with delayed neurological symptoms – extensive brain damage in the form of massive cortical necrosis, cortical blindness, epilepsy and spastic quadriplegia, and three were described as 'symptom-free' but had 'severe biological or neurological abnormalities'. Four of the children had been exposed in utero and after birth to AZT and 3TC (a similar drug) combined, and four to AZT alone. None were HIV-positive. Please see the annexed APPENDIX for an excerpt from this report detailing these injuries. Following further 'exhaustive' investigation by Barret et al., the 'hypothesis of a link' between perinatal AZT exposure and grave harm to unborn and newly born babies was 'confirmed'; see the report cited immediately below.)

Blanche et al. *Lancet* 354(9184):1084-9 (1999)

'An exhaustive study in a large prospective cohort [*of AZT- and 3TC-exposed children found*] unexplained symptoms compatible with mitochondrial dysfunction. A total of 2644 of 4392 children were exposed to antiretrovirals ... All the children with "established" or "possible" mitochondriopathy diagnosed in this study had been exposed to antiretroviral drugs ... in the pre, per- and post-partum periods. ... The finding that the use of antiretroviral nucleoside analogues in the perinatal period is associated with persistent mitochondrial disease is confirmed ... a risk about 30 times higher than that in the general population. ... Despite active screening, no similar cases were found in the antiretroviral unexposed group. ... by age 18 months ... a coherent syndrome is appearing with three main features: neurological symptoms (principally developmental retardation, seizures and behavioral disturbances), significant abnormalities on cerebral MRI (principally lesions of the white matter and brainstem) and often hyperlactataemia either persistent or transient outside the treatment period. First described

as a myopathy associated with zidovudine [AZT], the issue of mitochondrial toxicity of nucleoside analogues is currently a growing problem. Its clinical expression is highly variable, from peripheral neuropathy to severe lactic acidosis.'

Barret et al. *AIDS* 17(12):1769-1785 (2003)

'Mitochondrial dysfunction has been reported in HIV-negative children perinatally exposed to zidovudine [AZT], a drug often used in HIV-seropositive mothers during pregnancy. The purpose of this study was to determine the incidence of cerebral MR imaging findings in HIV-uninfected children exposed to zidovudine who present with unexplained neurologic symptoms. ... Images observed in children with antiretroviral-induced mitochondrial dysfunction are similar to those observed in congenital mitochondrial diseases.'

Tardieu et al. *American Journal of Neuroradiology* 26(4):695-701 (2005)

'AZT exposure causes a persistent depletion of mtDNA [(mitochondrial DNA) in babies exposed to AZT in the womb. Because] chemically induced tumors take 20 to 30 years to develop ... the possibility ... exists that exposed children might have an elevated cancer risk that will be manifested later in life. ... the results presented here underscore the necessity for long-term follow-up of children of HIV-infected mothers receiving prenatal HAART therapy.'

Poirer et al. *Journal of the Acquired Immune Deficiency Syndrome* 33(2):175-183 (2003)

'The probability of developing severe disease at 3 years of life was significantly higher in children born to mothers [administered AZT during their pregnancies] than in those born to [untreated] mothers. ... The same pattern was observed for severe immune suppression: the probability of developing severe immune suppression was significantly higher in children born to [AZT-treated] mothers ... than born to [untreated] mothers. ... Finally, survival probability was lower among children [born to AZT-treated mothers] ... compared with children born to [untreated] mothers.'

De Martino et al. *AIDS* 13(8):927-33 (1999)

'Prenatal and perinatal ZVD [AZT] exposure were associated with 1.8-fold increased risk of progression to AIDS or death after adjusting simultaneously for all variables associated with disease progression ... Restricting the analysis to children born after April 1994 (date of public release of the results of ACTG 076), ZDV exposure was associated with 2.5-fold increased risk of progression to AIDS or death after adjusting simultaneously for the same variables. ... Steady improvements in prognosis of [HIV] infected children unexposed to ZVD were observed in each successive birth cohort, but infected children exposed to ZVD lagged behind these temporal changes. Our results ... are consistent with recent results from the Italian Registry for HIV Infection in Children [reported by de Martino, cited above].'

Kuhn et al. *Journal of Infectious Diseases* 182(1):104-11 (2000)

'In this retrospective study, the risk of RPD [*rapid progression of disease*] was five to six times higher among infants born to [AZT] treated compared with untreated mothers. ... RPD was three times more likely to occur in infants born to [AZT] treated compared with findings in untreated mothers.'

De Souza et al. *AIDS* 24(2):154-61 (2000)

'AZT-exposed [*Macaca nemestrina monkey*] infants took three times as many sessions (6) as controls (2) to meet criterion on Black-White Learning, a simple discrimination task [and performed] significantly [worse in locating] the reward. ... Postnatal weight increase was significantly lower in AZT-exposed infants ... Hemoglobin dropped significantly in the AZT-treated animals after treatment began and remained low until the end of the study ... The hematological toxicities reported here are consistent with those seen in 500 mg/day AZT-treated humans.'

Ha et al. *Journal of Acquired Immune Deficiency Syndromes and Human Retrovirology* 7(2):154-7 (1994)

'The AZT animals [*Macaca nemestrina monkeys given AZT during pregnancy*] developed an asymptomatic macrocytic anemia, but hematologic parameters returned to normal when AZT was discontinued. Total leukocyte count decreased during pregnancy and was further affected by AZT administration. AZT caused deficits in growth, rooting and snouting reflexes, and the ability to fixate and follow near stimuli visually.'

Ha et al. *Journal of Acquired Immune Deficiency Syndromes and Human Retrovirology* 18(1):27-38 (1998)

'The study cohort included 92 HIV-1-infected and 439 uninfected children ... Antiretroviral therapy (nonprotease inhibitor) was independently associated with FTT [*Failure to Thrive*] in our cohort ... ZDV [AZT], in particular, alters mitochondrial metabolism and may have direct nutritional effects.'

Miller TL et al. *Pediatrics* 108(6): 1287-96 (2001)

'Antiretroviral drugs (ARV) as prophylaxis to prevent mother-to-child transmission of HIV results in decreased haematological parameters during and shortly after exposure, with recent data suggesting a more prolonged inhibition of haematopoiesis until at least 18 months [*i.e. ARV drugs given to pregnant women cause persistent bone marrow suppression reducing blood cell production*]. In uninfected children ... ARV exposure [before birth was] associated with reduced neutrophil count until at least 8 years of age. ... CONCLUSION: A considerably longer effect of exposure to ARV was shown in uninfected children than previously thought.'

European Collaborative Study, *AIDS* 18(15):2009-17 (2004)

'[In a major review of data collected between 1986 and April 2004, AIDS drugs such as AZT were found to cause a] substantially increased risk of severely curtailed pregnancy [*i.e. dangerously critical prematurity*] ... coupled with a very high neonatal mortality rate.'

Thorne et al. *AIDS* 18(17):2337-2339 (2004)

'Premature infants of HIV-positive mothers may be more likely to develop a rare, but potentially fatal, bowel condition, according to French research [*by Desfrere et al.*] published in the September 23rd [2005] edition of *AIDS* [19:1487-1493]. In a retrospective study the investigators found that having an HIV-positive mother was an independent risk factor for developing necrotising enterocolitis in babies born before the 37th week of pregnancy. The investigators suggest that mitochondrial toxicity, resulting from the use of AZT to prevent mother-to-child transmission of HIV, is a possible cause. ... Necrotising enterocolitis is a gastrointestinal disease which can affect premature infants and can result in destruction of the bowel. ... Of the 30,000 infants born at the investigators' unit, 4009 were premature. A total of 79 (2%) of these premature infants developed necrotising enterocolitis. The incidence of necrotising enterocolitis was 2% (72/3931) in the premature infants of HIV-negative mothers, but 9% (7/78) in the premature infants of HIV-positive mothers. None of the seven infants born to HIV-positive mothers were infected with HIV. ... All seven infants with necrotising enterocolitis and an HIV-positive mother received doses of AZT to prevent mother-to-child transmission of HIV. Six of the seven mothers were also taking anti-HIV therapy; in two this consisted of AZT monotherapy, the other four women were taking a three-drug combination (AZT or ddI with 3TC and a protease inhibitor).'

Michael Carter, *AIDSmap News*, 7 September 2005

'Children born to HIV-positive women who take antiretroviral therapy (ART) during pregnancy are significantly smaller in terms of height, weight and head circumference compared with children born to HIV-positive women not on ART, or who took monotherapy, according to the results of a European study examining the effects of ART on uninfected children's growth up to the age of 18 months [*European Collaborative Study*, *JAIDS* 40(3):364-370 (2005)].'

Edwin Bernard, *AIDSmap News*, 3 November 2005

'Two new animal studies [*Walker et al.*; *Hong et al.*] have examined the cancer-causing effects of transplacental exposure to AZT in mice and rats and found increased rates of tumors and tumors with gene changes that frequently occur in human cancer. In addition, two human studies [*Escobar et al.*; *Witt et al.*] are the first to observe the induction of mutations and large scale chromosomal damage in red blood cells of newborns exposed to NRTIs [*nucleoside analogue reverse transcriptase inhibitors*] in utero. These, and other, studies were published in April 2007 in a special issue of *Environmental and Molecular Mutagenesis* that examines the latest research on DNA damage and potential health risks related to the use of NRTIs.

Besides the effects of NRTIs on nuclear DNA and cancer risk, the issue also contains recent findings on the toxicity of these drugs toward mitochondrial DNA.'

Science Daily, 7 April 2007

APPENDIX

Blanche et al. describe eight children severely harmed by AZT exposure in the womb and post-natally, two fatally, in 'Persistent mitochondrial dysfunction and perinatal exposure to antiretroviral nucleoside analogues', *Lancet* 1999 Sep 25;354(9184):1084-9.

Note that in all cases the crippling injuries caused by AZT during gestation and after birth were not immediately evident, but only became apparent several months later.

And in common with the others cited above, the researchers do not consider and report the likelihood of widespread subclinical, undiagnosable, permanent neurological and mental/psychological impairment resulting from AZT exposure in utero and after birth.

'At age 4.5 months, the first patient presented with visual impairment. Cerebral nuclear magnetic resonance imaging showed initially (at age 5.0 months) demyelinating lesions of the brainstem that became more severe and secondarily associated (at 11.0 months) with sustentorial lesions. From age 4.5 months to 11.0 months, the growth was abnormal and associated with vomiting. There were no important hepatic, pancreatic, muscle enzyme, or haematological abnormalities, but blood and cerebrospinal fluid lactate concentrations were high (2.5 mmol/L [normal <1.5 mmol/L] and 4.5 mmol/L [<2.0 mmol/L], respectively). The child died aged 13 months because of respiratory and cardiac-rhythm disorders. The symptoms were compatible with Leigh's syndrome and mitochondrial investigations were done at age 12 months.

'The second patient, from age 4 months until death at 11 months, had refractory epilepsy and deterioration of cognitive and psychomotor abilities. Cerebral imaging showed diffuse demyelinating lesions associated with massive cortical necrosis (figure). There were no substantial biological abnormalities for liver, pancreas, muscle, or haematological markers. The blood lactate concentration was high (2.5 mmol/L) but cerebrospinal fluid lactate was normal. Several disorders were excluded because of normal results from the following diagnostic procedures: organic-acid chromatography (urine), aminoacid chromatography (serum, urine, cerebrospinal fluid), serum cholesterol, triglycerides, vitamins A and E, pyruvate dehydrogenase activity in lymphocytes, fatty-acid oxidation and biotinidase activities (lymphocytes), very long-chain fatty acids (serum), lysosomal enzymes (galactosidase, galactosylceramidase, arylsulfatase A, mannosidase, GM1 and GM ganglioside), copper and ceruloplasmin (serum), and oligosaccharide excretion (urine). These symptoms were consistent with ALPERS syndrome, and led to mitochondrial investigations between ages 5 months and 7 months.

'At age 8 months, during a febrile episode, patient three had a seizure and was thought to be hypotonic. At age 15 months, the child showed symptoms of hypokinetic hypertrophic cardiomyopathy. Blood hepatic and pancreatic enzyme concentrations were normal but the child had neutropenia neutrophils 0.931 09/L [normal > 1.531 09/L], high concentrations of muscle creatine phosphokinase in blood (350 IU/L [<250 IU/L]), and persistently high blood lactate concentrations (4mmol/L), although cerebrospinal lactate was normal. Endomyocardial biopsy showed intracytoplasmic vacuolisation in myocytes, but without inflammation. The cardiomyopathy progressively improved and symptoms of peripheral myopathy were seen at age 2.5 years. At age 4.0 years, the child's cardiac function was normal, but moderate muscular deficit persisted; lactate and muscle creatine phosphokinase concentrations in blood remained high. Electroretinography showed macular and peripheral abnormalities. Cerebral nuclear magnetic resonance imaging was normal.

'In the fourth patient, early development was normal. Between ages 14 months and 27 months, the child had four episodes of febrile seizures. Neurological assessment at age 27 months showed mild spastic diplegia. Haematological and biochemical findings, including lactate concentrations in blood and cerebrospinal fluid, were normal. Cerebral nuclear magnetic resonance imaging showed moderate hypersignal of the white matter in T2-weighted images, with no evidence of necrosis (figure).

'From age 7 months until 15 months, patient five had repeated seizures. Cognitive development and neurological assessments between episodes were normal until age 15 months. The child developed status epilepticus for 4 h, which led to severe neurological dysfunction with cortical blindness and spastic tetraparesis. Biological tests at 15 months showed only high blood hepatic enzyme concentrations (aspartate and alanine aminotransferases 200 IU/L [<40 IU/L]), which progressively returned to normal. Blood and cerebrospinal fluid lactate concentrations were measured only at the time of mitochondrial assessment and were not retrospectively available. Nuclear magnetic resonance imaging at age 16 months showed large necrotic lesions of the white matter and cortical grey matter. At age 3.5 years the child had severe sequelae and microcephaly.

'Patient six was symptom-free until age 14 months, but persistent biochemical abnormalities were seen on standard follow-up of the epidemiological survey (which included lactate assays). The child had had high concentrations of blood lactate (4 mmol/L), hepatic aspartate aminotransferase (50 IU/L), and pancreatic lipase (200 IU/L [<150 IU/L]) since birth that persisted until age 14 months. Cerebrospinal fluid lactate was normal. These biological abnormalities led to specific mitochondrial investigation, including cerebral nuclear magnetic resonance imaging that showed delayed myelinisation, which is difficult to interpret at that age.

'Patient seven was symptom-free until age 4 months, at which time he became hypotonic with apnoea. The child regained normal breathing and consciousness after resuscitation, with no apparent sequelae. There were no biological abnormalities during routine biological follow-up, but blood lactate concentrations (routinely assayed in this institution) were continuously high (>4 mmol/L) from the first test at 4 weeks to 7 months. Cerebral nuclear magnetic resonance imaging was normal. Near-miss syndromes and lactataemia justified mitochondrial investigations.

'The eighth child was symptom-free. Persistent hepatic and pancreatic abnormalities (alanine aminotransferase 80 IU/L and lipase 180 IU/L) were seen from birth in the routine prospective biological follow-up. Blood lactate concentrations that were systematically added to the normal screening in the institution were normal, as were cerebrospinal fluid concentrations. At age 20 months, biological abnormalities persisted unchanged; a specific mitochondrial investigation was therefore done, including electroretinography, which was abnormal, and cerebral nuclear magnetic resonance imaging that showed abnormalities of the periventricular white matter.

'No child was infected with HIV-1, and all were HIV-1 seronegative at age 15 months, or at death before this age for patients one and two. For all children, repeated tests for HIV-1 by PCR and by culture were negative.'

NOTE

For a comprehensive review of the medical and scientific research literature on the foetal and neonatal toxicity of AZT and similar nucleoside analogue drugs, and for a critical discussion of WHO, UNAIDS, UNICEF and US CDC recommendations regarding the use of these drugs in pregnancy, see *Poisoning our Children: AZT in Pregnancy* by Adv Brink – online in the 'Quick links' column at www.tig.org.za.

Even as they report the harm that ARV exposure causes babies in the womb, many researchers continue to support the use of such drugs in pregnancy on the basis that they prevent mother to child transmission of HIV, and thereby save lives. In fact, there is no evidence supporting the notion that children born to HIV-positive mothers given AZT (and/or other ARVs) live, whereas children born to untreated mothers will get seriously sick and die; as the research findings cited above demonstrate, the contrary is the case.

Whether ARVs such as AZT really do prevent mother to child transmission of HIV is examined and debunked in an extensive analysis by Papadopoulos-Eleopoulos et al., *Mother to*

Child Transmission of HIV and its Prevention with AZT and Nevirapine: A Critical Analysis of the Evidence (monograph, 2001) – also online in 'Quick links' at the **TIG** website.

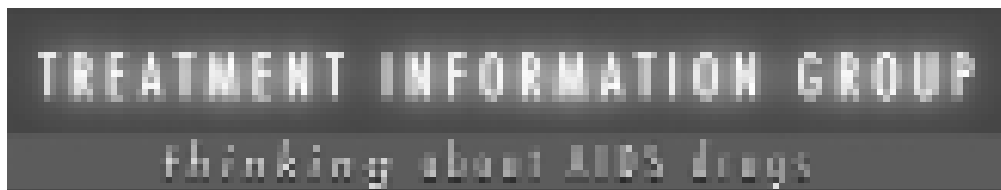The TAC's call for AZT and similar drugs to be given to pregnant African women and their newborn babies in South Africa is supported by Nicoli Nattrass, Professor of Economics, University of Cape Town; by Ferial Haffajee, editor of the *Mail&Guardian*, backed by the newspaper's governing board; and by Kerry Cullinan, editor of Health-e, an AIDS drug promoting news service.

The reason for general ignorance in South Africa about the harm that AZT causes unborn and newly born children is because the dissemination of information about it has been banned in the commercial media. On 22 November 2004 the Treatment Information Group (TIG) summarized the above-cited research findings in an article in the *Mail&Guardian*: 'Numerous studies have found that children exposed to AZT in the womb suffer brain damage, neurological disorders, paralysis, spasticity, mental retardation, epilepsy, other serious diseases and early death', preceded by the note that 'Hundreds of studies have found that AZT is profoundly toxic to all cells of the human body, and particularly to the blood cells of our immune system.' Outraged public reaction to the statement of these unacceptable facts led M&G editor Haffajee to apologize for publishing them, and to promise readers never to do so again. On 9 March 2005, following a complaint by the TAC, the Advertising Standards Authority proscribed the offending statements; and consequently they may not be repeated in the media, nor accepted for reproduction by any printing firm in South Africa.

On 28 October 2005 Medicines Control Council chairman Professor Peter Eagles wrote to say that his MCC was unconcerned by research reports concerning the foetal and neonatal toxicity of AZT, which the TIG had drawn to its attention, and said the MCC stood by its recommendation in July the year before that the drug be given to pregnant African women and their newborn babies (see the correspondence in *Poisoning our Children: AZT in Pregnancy*). The MCC's indifference to these reports may possibly be explained by the fact that its members are predominantly white and Indian.

✳ 'With great honesty the TAC has always tried to understand medical science. And this is something with which all South Africans have always struggled. We are scientifically illiterate.'

**Zackie Achmat, leader of the Treatment Action Campaign,
Rapport (translated from Afrikaans), 10 February 2002**



WWW.TIG.ORG.ZA • INFO@TIG.ORG.ZA • TEL 021 4249793 • FAX 021 4201776
P.O. Box 1000, Durban, South Africa • PO Box 1000, Durban, South Africa